

A Fixed Reverse Labial Bow for Moderate Class III Interceptive Treatment

ALDO CARANO, DO, MS
S. JAY BOWMAN, DDS, MSD
MARCO VALLE

The treatment of skeletal Class III malocclusion, particularly in the late deciduous or early mixed dentition, is one of the most challenging problems confronting the orthodontist. These patients frequently exhibit anterior or posterior crossbites, in addition to some combination of maxillary skeletal retrusion and mandibular skeletal protrusion.

Although good treatment results have been achieved with either reverse-pull headgears¹⁻¹¹ or functional appliances,¹²⁻¹⁶ the results can be com-

promised by poor patient cooperation, since such Class III appliances tend to be uncomfortable and unesthetic. This article presents a new approach to the management of mild-to-moderate dental and skeletal Class III malocclusions in growing patients, without relying on special patient cooperation.¹⁷

Appliance Design

The SW III consists of an .045" stainless

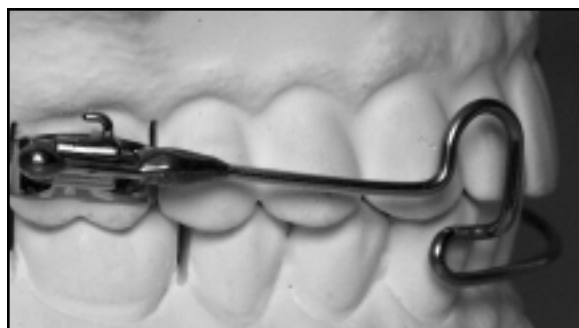
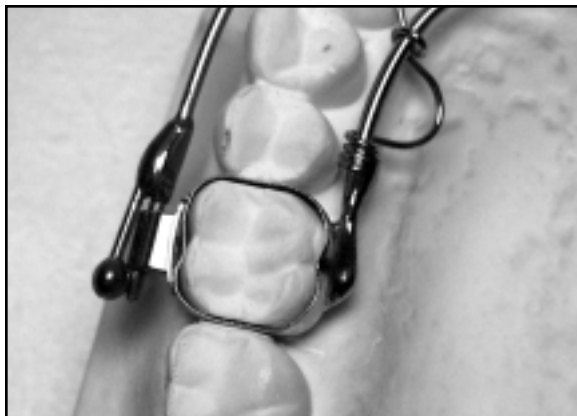
Fig. 1 SW III consists of .045" stainless steel archwire inserted into upper molar headgear tubes, with clips at each distal end for retention.

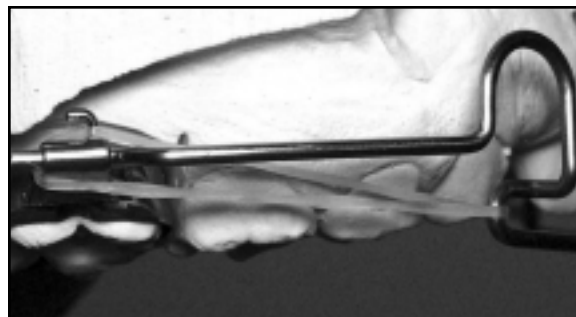
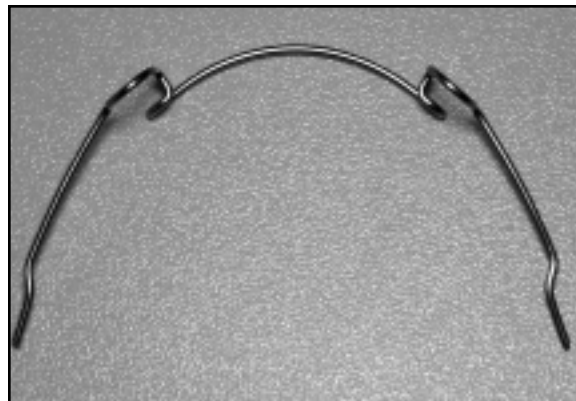


Fig. 2 SW III without distal clip. Bayonet bend acts as distal stop; elastics between distal end of wire and anterior portion of facebow ensure stability during mandibular closure.

Dr. Carano is an Adjunct Professor at St. Louis University and a Visiting Professor at the University of Ferrara, Italy. He is in the private practice of orthodontics at Lungomare 15, 74100 Taranto, Italy; e-mail: carano@libero.it. Dr. Bowman is an Adjunct Associate Professor at St. Louis University and the straightwire instructor at the University of Michigan. He is in the private practice of orthodontics in Portage, MI. Mr. Valle is a laboratory technician in Lecce, Italy.



Dr. Carano



Dr. Bowman



Mr. Valle

steel archwire that is inserted into the headgear tubes of the upper molar bands (Fig. 1). The anterior part of the wire restricts the lower incisors during closure of the mandible. Each distal end has a clip fabricated from an .028" piece of wire, 7mm long, ending in a distal ball end soldered to a 3mm tube (internal diameter 1.2mm). The clip prevents the ends of the wire from sliding out of the molar tubes. Normally, the patient is instructed to remove the labial bow for eating, but in especially uncooperative patients it can be ligated to the molar tubes.

A variation of this design without the distal clips has recently been developed (Fig. 2). After measuring the wire in the patient's mouth, the clinician adds terminal stops by making bayonet bends with a birdbeak plier. To ensure the stability of the appliance during closure, elastics are attached between the distal ends of the wire and the anterior portion of the facebow. This version requires a higher level of patient compliance and thus will not be suitable for all cases.

Restriction of the lower arch and the mandible is only one of the orthodontic effects required during interceptive treatment of moder-

ate Class III malocclusions. Therefore, the SW III is always used in conjunction with one or more other maxillary fixed appliances, such as a rapid palatal expander¹⁸ (Fig. 3), a palatal arch for incisor advancement (Fig. 4), or a tongue crib. The lower arch can be left free or can be prepared with a lingual arch for anchorage, depending on how much lingual inclination of the lower incisors is required during treatment.

Case Report

An 8-year-old male presented with an open bite and a moderate dental Class III malocclusion with a skeletal Class III tendency (Fig. 5). He was treated with the SW III, while the functional interference of a tongue-thrust habit was corrected with a soldered tongue crib (Fig. 6). He wore the SW III 24 hours a day except during meals.

The malocclusion was corrected in five months. The SW III was left in place for one year to control mandibular growth, and thereafter was worn only at night for retention.

This first phase of treatment produced a good dental Class I occlusion and orthopedic

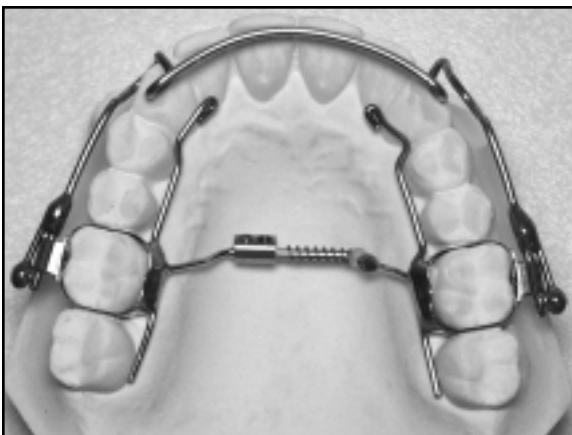


Fig. 3 SW III combined with palatal expander.

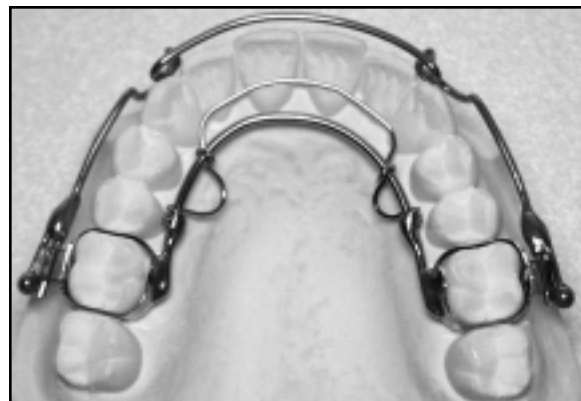


Fig. 4 SW III combined with palatal arch for incisor advancement.

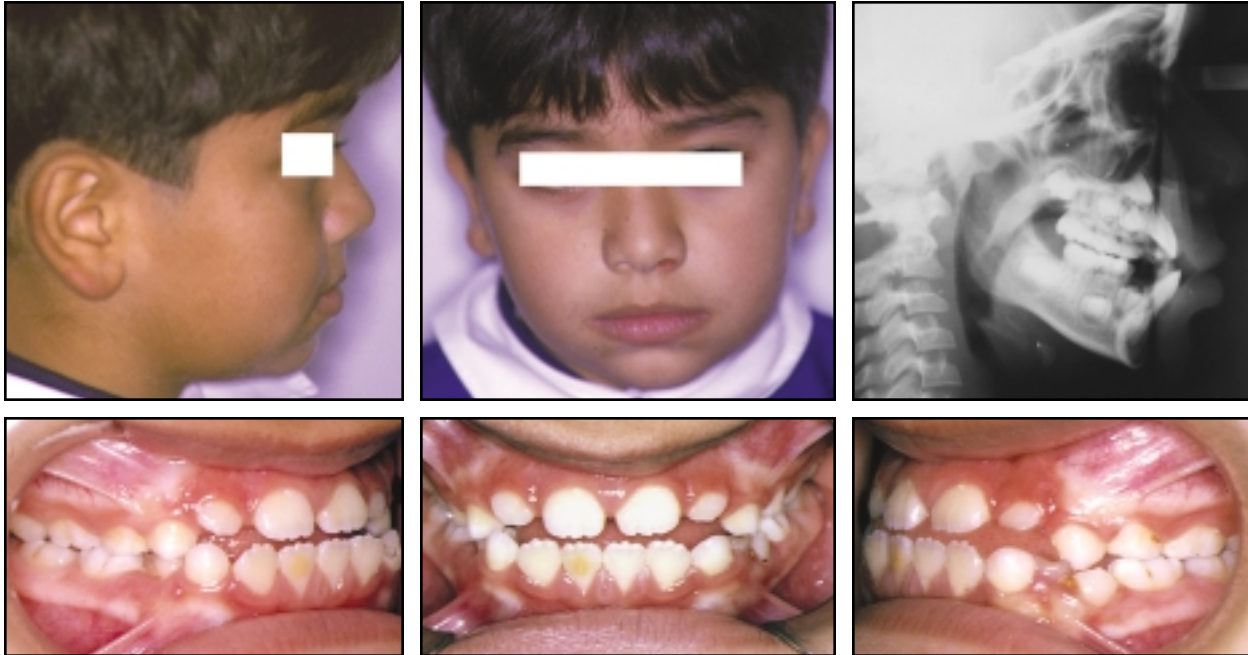

Fig. 5 8-year-old male patient with Class III malocclusion and open bite before treatment.

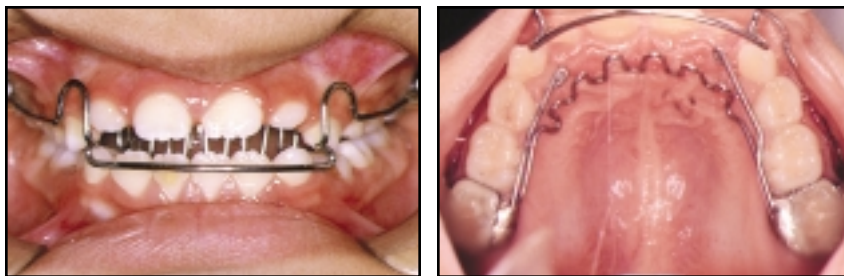


Fig. 6 Placement of SW III and soldered tongue crib.

facial balance (Figs. 7,8). The results remained stable two years later (Fig. 9).

Discussion

The objective of interceptive treatment of a moderate Class III malocclusion is to reestablish incisal guidance and harmonious interdigitation. Most Class III patients begin to develop an initial functional shift of the mandible during childhood. To counteract that tendency during maturation, the SW III guides the mandible into a centric relationship. The Frankel III, the bionator III,

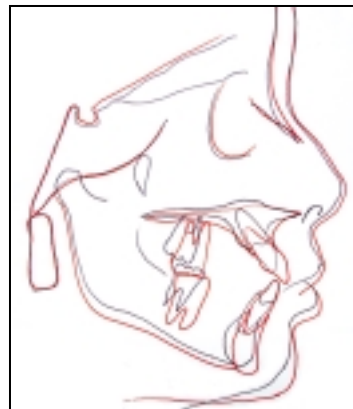


Fig. 7 Superimposition of cephalometric tracings before and after treatment.

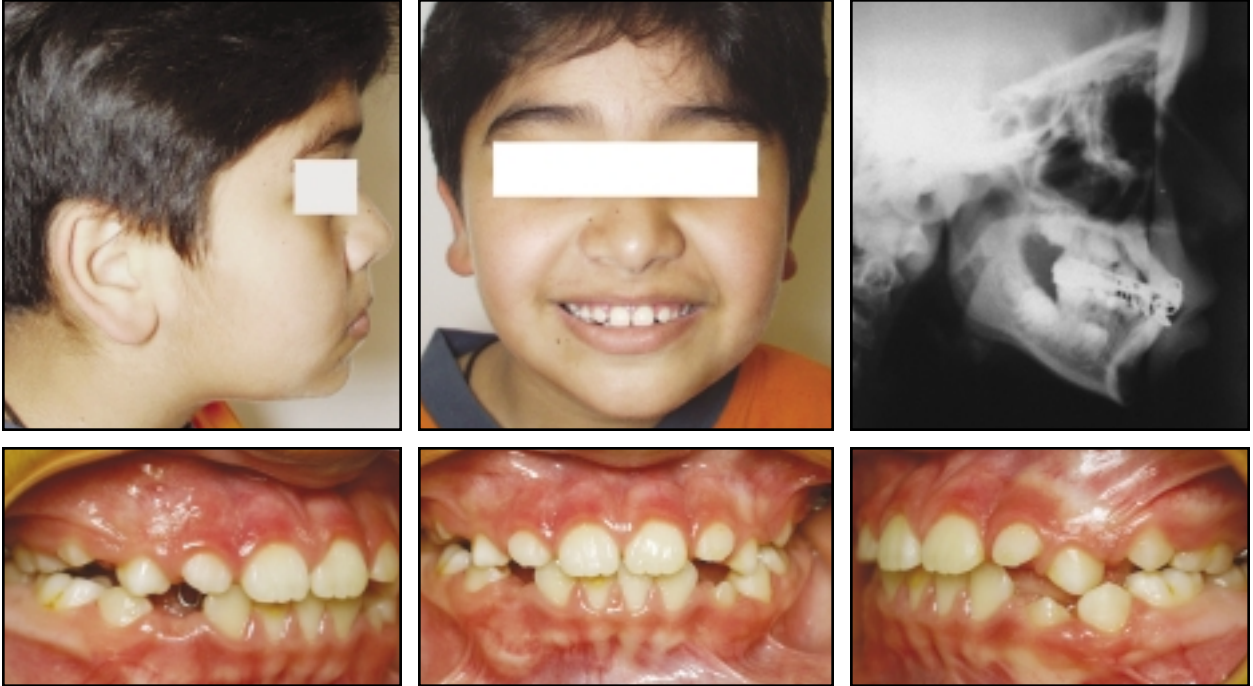


Fig. 8 Patient after one year of treatment, showing Class I occlusion and facial balance.

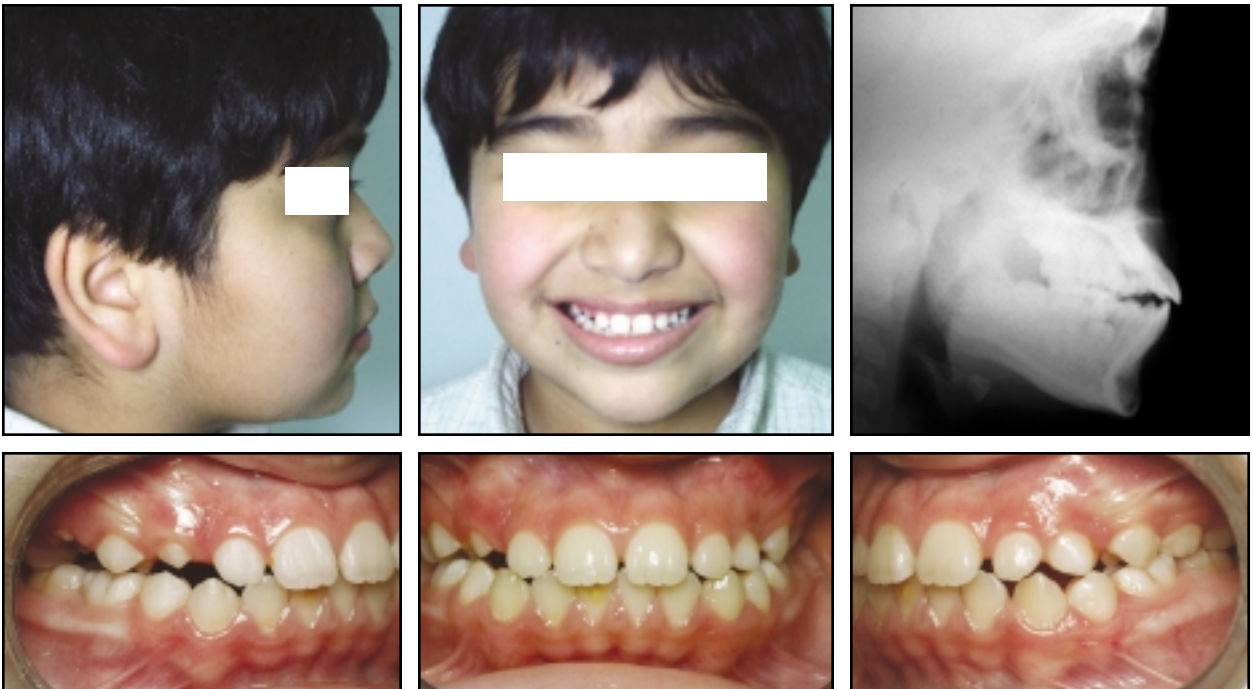


Fig. 9 Stability of results two years after first phase of treatment.

and the modified Hawley appliance for Class III treatment^{19,20} all have the same effect of inhibiting the lower incisors during mandibular closure, but require more patient compliance.

Another characteristic of functional appliances that was adapted for the SW III is the reverse labial bow for controlling the sagittal discrepancy and establishing incisor overlap. Conventional fixed appliances, such as the tongue crib shown here, are used simultaneously to correct the interarch imbalance.

The results are predictable and rapid, usually occurring within two to four months. As seen in the present case, ANB generally increases due to an increase in SNA, with no downward and backward rotation of the mandible. The lower incisor inclination decreases, while the overbite and overjet are improved.

The SW III is then left in place for retention, usually for no longer than a year. After that, the patient can wear a functional appliance at night, if necessary, until the complete eruption of the permanent dentition, when the need for further orthodontic treatment or surgery can be evaluated. The SW III can be reused as a retainer at the conclusion of treatment.

REFERENCES

1. Turley, P.K.: Orthopedic correction of Class III malocclusion with palatal expansion and custom protraction headgear, *J. Clin. Orthod.* 22:314-325, 1988.
2. McNamara, J.A. Jr.: An orthopedic approach to the treatment of Class III malocclusion in young patients, *J. Clin. Orthod.* 21:598-608, 1987.
3. Postpeschnigg, W.: *Deutsche Vierteljahrsschrift für Zahnheilkunde*, Monthly Rev. Dent. Surg. 3:464-465, 1875.
4. Delaire, J.: Confection du masque orthopedique, *Rev. Stomatol. Chir. Maxillofac.* 72:579-584, 1971.
5. Petit, H.: Adaptations following accelerated facial mask therapy, in *Clinical Alteration of the Growing Face*, ed. J.A. McNamara, K.A. Ribbens, and R.P. Howe, Monograph No. 14, Craniofacial Growth Series, University of Michigan, Ann Arbor, 1983, pp. 48-59.
6. Mermigos, J.; Full, A.; and Andreasen, G.: Protraction of the maxillofacial complex, *Am. J. Orthod.* 98:47-55, 1990.
7. Nanda, R.: Biomechanical and clinical considerations of a modified protraction headgear, *Am. J. Orthod.* 78:125-139, 1980.
8. Cozzani, G.: Extraoral traction and Class III treatment, *Am. J. Orthod.* 80:638-650, 1981.
9. Grummons, D.: *Orthodontics for the TMJ-TMD Patient*, Wright & Co., Scottsdale, AZ, 1994.
10. Graber, L.W.: Chin cup therapy for mandibular prognathism, *Am. J. Orthod.* 72:23-41, 1977.
11. Conte, A.; Carano, A.; and Siciliani, G.: A new maxillary protractor, *J. Clin. Orthod.* 31:523-530, 1997.
12. Ülgen, M. and Firatli, S.: Effects of Fränkel's function regulator on the Class III malocclusion, *Am. J. Orthod.* 105:561-567, 1994.
13. Fränkel, R.: Maxillary retrusion in Class III and treatment with the function corrector III, *Trans. Eur. Orthod. Soc.* 46:249-259, 1970.
14. Kerr, W.J.S. and Ten Have, T.R.: A comparison of three appliance systems in the treatment of Class III malocclusion, *Eur. J. Orthod.* 10:203-214, 1988.
15. Kerr, W.J.S.; Ten Have, T.R.; and McNamara, J.A. Jr.: A comparison of skeletal and dental changes produced by function regulators (FR-2 and FR-3), *Eur. J. Orthod.* 11:235-242, 1989.
16. Garattini, G.; Levrini, L.; Crozzoli, P.; and Levrini, A.: Skeletal and dental modifications produced by the bionator III appliance, *Am. J. Orthod.* 114:40-44, 1998.
17. Carano, A.; Balsamo, L.; and Siciliani, G.: Treatment of the noncompliant Class III growing patient, *Clin. Orthod. Res.* 4:35-42, 2001.
18. Carano, A. and Testa, M.: The Spring Jet for slow palatal expansion, *J. Clin. Orthod.* 33:527-531, 2000.
19. Tenti, F.V.: Class III orthopaedic treatment, in *Atlas of Orthodontic Appliances*, English ed., Caravel Co., Genoa, Italy, 1986, p. 249.
20. Wang, F.: Inverted labial bow appliance for Class III treatment, *J. Clin. Orthod.* 30:487-492, 1996.