



good PRACTICE

Perspectives and Insights for the Orthodontic Profession

VOLUME 2 NO. 2

Page 2

Accelerating Orthodontics by Altering Alveolar Bone Density
Dr. Donald J. Ferguson, DMD, MSD
Dr. William M. Wilcko, DMD, MS
Dr. Thomas M. Wilcko, DMD



Page 5

Improvements in Pre-Adjusted Appliances: Butterfly Brackets
Dr. S. Jay Bowman, DMD, MSD
Dr. Aldo Carano, DDS, MS



■ Meet the
new president
of AO ... page 4

■ Check out
what's new on
the back cover

Accelerating Orthodontics by Altering Alveolar Bone Density

Rapid tooth movement following surgery as a consequence of changes in the physiology and/or composition of alveolar bone has been demonstrated. Dr. Eric Liou recently presented a technique he called "dental distraction" whereby the mesial aspect of the socket of an extracted first premolar tooth was directly modified (surgically undermined) in such a way as to allow "distal distraction" of the adjacent cuspid. The alveolus or the periodontal ligament (PDL), or both, were forcibly distracted into a new configuration followed by reorganization. Dr. Liou claimed no adverse effects to the periodontal support and that the PDL re-established integrity after averaging 6.5 millimeters of cuspid retraction in 3 weeks (AJODO, 114:372, 1998).

More recently, Drs. Bill and Tom Wilcko have demonstrated rapid orthodontic tooth movement following selective labial and lingual decortication of alveolar bone in the area of desired tooth movement using a patented/trademarked technique called Accelerated Osteogenic Orthodontics™ (AOO™)* (Fig. 1). Dental arch crowding is routinely resolved and the finishing stage is completed in 4-6 months of active orthodontic treatment following the corticotomy surgery and alveolar grafting (Int J Perio Restor Dent, 21:9, 2001).


An orthodontic Masters thesis by Hajji was conducted to determine the differences among conventional non-extraction,

Donald J. Ferguson, DMD, MSD
William M. Wilcko, DMD, MS
Thomas M. Wilcko, DMD

conventional extraction and the AOO techniques on lower dental arch de-crowding. It was discovered that AOO therapy averaged 6.1 months while conventional non-extraction and extraction therapies averaged 18.7 and 26.6 months, respectively. Furthermore, the post treatment status of the lower dental arch following cephalometric and study cast analysis were statistically no different in the AOO subjects when compared to the non-extraction group (Hajji SS, Masters thesis, Saint Louis University, 2000).

The AOO technique is more difficult to conceptualize than dental distraction in that rapid tooth movement is not forced but rather takes place after the periodontal supporting structures are induced into an altered condition. It is apparent that the alveolar hard and soft tissues undergo rapid transformation as the body attempts to heal the corticotomy wounds. The accelerated reorganization of alveolar bone results in a transient condition called osteopenia characterized by a decrease in mineral content and an increase in osteoid type bone. This condition bears a resemblance to what orthodontists refer to as undermining resorption but is different in that osteopenia is widespread and pervasive adjacent to the corticotomy surgery.

How AOO non-extraction orthodontic



Dr. Ferguson is Professor of Orthodontics at St. Louis University.



Dr. William Wilcko has been in the private practice of orthodontics in Erie, Pennsylvania for the past 18 years.



Dr. Thomas Wilcko has been in the private practice of periodontics in Erie, Pennsylvania for the past 25 years.

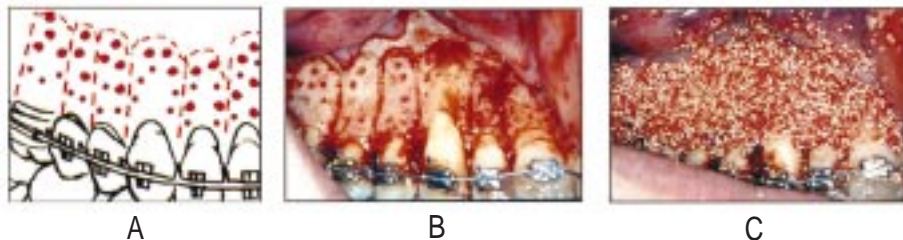


FIG 1: AAO Technique
A: Inter- and supra-dental corticotomy diagram. B: AAO corticotomy. C: AAO grafting

* AOO™ is patented and trademarked by Wilckodontics, Inc.

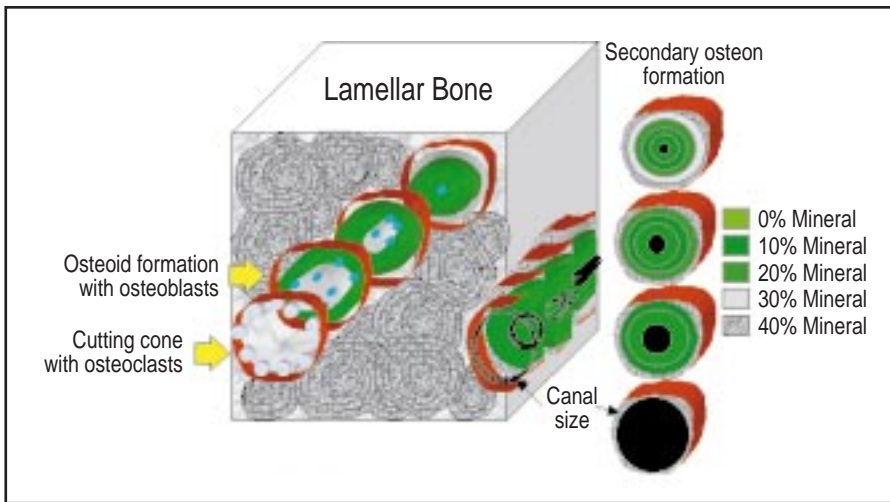


FIG 2: Osteocytic osteolysis within trabecular lamellar bone showing cutting cone and secondary osteon formation. Osteoclasts is followed by bone apposition and osteoid formation. Mineralization begins between 20 to 55 days after osteoid formation.

therapy can produce treatment results identical with that achieved in conventional non-extraction therapy, but in one-third the treatment time (6.1 versus 18.7 months), is a cause for reflection. How is tooth movement under these conditions different from the orthodontic tooth movement we know so well as cell mediated in the periodontal ligament? What has happened as a consequence of the intervening surgery?

Alveolar Osteopenia

The alveolus is comprised of lamellar bone and configured into cortical bone plates (compacta) and trabecular bone (spongiosa). In the steady state condition, bone apposition and mineralization is balanced. It takes much less time to remodel trabecular than cortical bone because of the difference in surface volume ratios (compacta is thicker than spongiosa). In alveolar osteopenia, rich deposits of calcium are released predominately from the spongiosa by two forms of osteoclastic activity: osteoclasts (surface resorption) and osteocytic osteolysis (osteon remodeling). This catabolic condition is followed by deposition of new bone. The new bone, osteoid, begins to mineralize in about 20 to 55 days (Fig. 2).

The induction of the alveolar structures into a more pliable condition favoring rapid tooth movement, i.e. osteopenia, can be initiated by any form of noxious in-

sult to the area; in the AOO technique, the corticotomy procedure is used. Labial and lingual surgical flaps are elevated and the cortical bone adjacent to the teeth to be moved is scored with a surgical bur penetrating barely into medullary bone. AOO technique employs a bone graft over the bleeding cortical bed but the graft is not essential to inducing alveolar osteopenia. After corticotomy, the alveolus becomes temporarily demineralized. This condition, alveolar osteopenia, favors and facilitates tooth movement.

Healing is the body's response to reorganizing tissues following injury such as surgery and includes hard and soft tissue remodeling. Distinguished orthopedist, Harold Frost, observed a direct correlation between degree of injury and intensity of physiological healing response, which he coined Regional Acceleratory Phenomena (RAP). RAP does not provide new healing processes but rather explains the acceleration of normal healing events; the greater the insult, the more accelerated and intense the regional healing response. RAP begins within a few days of the insult and typically peaks at 1 to 2 months, but may take as long as 2 years to subside (Clin Orthop & Related Res 248:283, 1989).

Corticotomy surgery initiates and potentiates normal healing processes (RAP) by way of an accelerated, transient

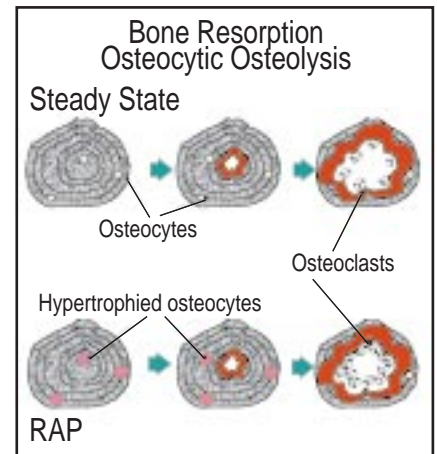


FIG 3: Diagrammatic comparison of steady state versus RAP induced bone resorption with hypertrophied osteocytes and increased number of osteoclasts.

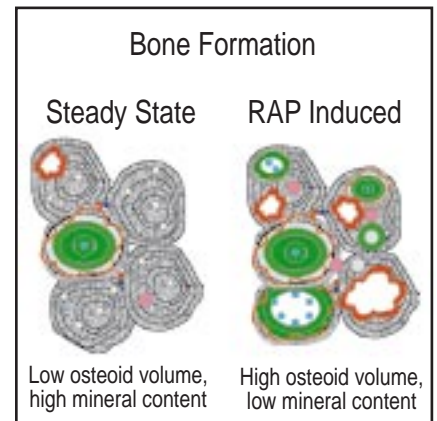


FIG 4: Diagrammatic comparison of steady state versus RAP induced bone formation with high amount of demineralized bone (osteoid).

burst of hard and soft tissue remodeling (Fig. 3). Bogoch found a five-fold increase in bone turnover in a long bone adjacent to a corticotomy surgery site (J Orthop Res 11:285, 1993). In alveolar bone adjacent to corticotomy, there is a marked increase in regional bone turnover due to activation of new remodeling. Calcium is released from alveolar bone creating a reversible demineralized condition (alveolar osteopenia) resulting in a decrease in bone mass (mineral content or density) but no change in bone volume.

Osteopenia and Rapid Tooth Movement

Corticotomy surgery results in a substantial increase in alveolar demineralization,

a transient and reversible condition (Fig. 4). Radiographically, a greater fraction of spongiosa than compacta temporarily disappears owing to the surface: volume ratio differences. Longitudinal tunneling takes place in cortical bone while both surface resorption and osteocytic osteolysis converts as much as 50% of local trabecular bone to osteoid in six weeks causing the spongiosa to markedly decrease or vanish on x-rays. The osteopenia enables rapid orthodontic tooth movement because teeth are supported by and moved through trabecular bone. As long as tooth movement continues, the RAP is prolonged. When RAP dissipates, the osteopenia disappears and the radiographic image of normal spongiosa reappears. When orthodontic tooth movement is completed and retainers are delivered, an environment is created that fosters alveolar re-mineralization.

When is Rapid Tooth Movement Appropriate?

Reference has been made to two orthodontic treatment techniques both resulting in rapid tooth movement (AOO and dental distraction) and both advocating invasive surgery (corticotomy and undermining the extraction site, respectfully). Although surgical invasion seems excessive and unnecessary in light of conventional orthodontic therapies, availability of the AOO technique resolves one fairly common patient grievance, "I want braces but the 2-year treatment time is unacceptable." The Wilckos offer the AOO technique when prompted by the patient and consider this service as an adjunct to routine orthodontic care; AOO procedures are rendered in about 5-10% of their orthodontic patient population.

The following patient presented with a Class I malocclusion with moderate crowding of both dental arches and was treated in 6 months utilizing the AOO technique (Fig. 5).

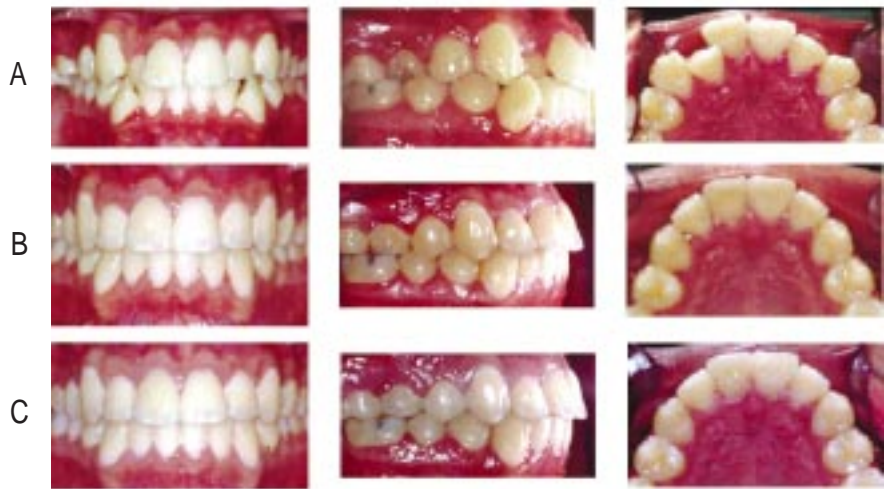

FIG 5: Late adolescent male patient with Class I, moderate dental arch crowding
 A: Pre-treatment
 B: Immediate post AOO treatment - 6 months and 3 days
 C: 1 year retention

A letter from Rich Iverson

After a little over four years away from the orthodontic business, I am returning to the industry by joining the American Orthodontics team in Sheboygan, Wisconsin. My previous experience includes thirty-three years with 3M Company from which I retired in April of this year. Eight years of that time were spent in the orthodontic industry.



Over the next several months I will be transitioning to assume the presidency from John Viglietti who will be retiring at the first of next year. John has led in an exceptional manner, and I feel honored to be selected as his successor. We will be working closely over the next several months to assure a seamless transfer.

My enthusiasm for returning to the orthodontic industry with American Orthodontics is threefold.

First, American Orthodontics is a successful company, well known for its outstanding customer service and quality.

Second, American Orthodontics is a highly ethical company with a long-term focus, as evidenced by its loyal customers and dedicated, hard working employees.

Third, I believe that my experience and strengths blend well with the culture of AO and I look forward to meeting the challenges and future growth potential of the company and of the orthodontic profession.

I intend to draw upon my enthusiasm and experience to stimulate, encourage and lead the company to new levels of achievement.

I want to extend my best wishes to you, our valued customers, and I eagerly anticipate meeting each of you. Your business will continue to be of utmost importance to all of us at American Orthodontics. Your comments, suggestions and thoughts are welcomed and encouraged at any time.

Very best regards,

Rich Iverson

Improvements in Pre-Adjusted Appliances: Butterfly Brackets

Part II of an interview with Drs. Bowman and Carano describing enhancements to a straightwire bracket system. In Part I, Dr. Bowman described common mistakes in treatment as reported in 1996 by the American Board of Orthodontics and proposed improvements in the concept of pre-adjusted appliances. In Part II, Drs. Bowman and Carano outline specific features of the new Butterfly bracket system.

Q: Can you briefly review the foundation for your proposed improvements for pre-adjusted appliances?

Bowman: In 1996, the American Board of Orthodontics (ABO) described the most common mistakes found in case reports presented by candidates failing the Phase III examination. These cases most likely represent fairly common errors facing a significant number of orthodontists. As straightwire appliances are so popular today, perhaps some of these ABO concerns could be directed to limitations of the straightwire concept and its clinical use. It seems reasonable that improvements in the straightwire concept may help to reduce the prevalence of these errors. Making use of Andrews' original concepts was an important first step in the development of the Butterfly system, but we needed to focus on modifications and enhancements.

Q: Did the American Board describe the use of pre-adjusted appliances as a concern?

Carano: No, the ABO's description of case failures did not direct specific concern to any particular treatment method or philosophy. Actually, the original straightwire concepts are intended to enhance an orthodontist's abilities to complete treatment more efficiently and effectively based, in part, on failures that Andrews' had found in so-called "ideal" finished cases.

Q: What is the Butterfly System?

S. Jay Bowman, DMD, MSD
Aldo Carano, DDS, MS



Carano: The Butterfly System is based on a new low-profile pre-adjusted bracket that features a vertical slot (**Fig. 1**). The vertical slot adds versatility to the appliance by permitting the addition of a variety of auxiliaries. For example, hook or T-pins for elastics can be added to the vertical slot during treatment whenever they are needed. This eliminates the need to have brackets manufactured with hooks.

Bowman: Further enhancement to patient comfort and esthetics is derived from the reduced profile or thickness of the bracket, its miniature Siamese twin design, and rounded tie-wings. Combining these features with the elimination of hooks results in an appliance that is more comfortable, esthetic, and hygienic.

Q: What are some of the features of the Butterfly Bracket System?

Bowman: There are seven unique features designed to improve upon existing pre-adjusted appliance concepts. These modifications were made in reaction to the findings of the American Board of Orthodontics and include: progressive posterior torque, reversible 2nd premolar angulation, preventative mandibular anterior torque, mandibular anterior progressive angulation, convertible molar tubes with -6° angulation pre-welded on the band, and added versatility for both non-extraction and extraction treatments. Finally, the versatile and indispensable vertical slot demonstrates a largely untapped potential.



Dr. Bowman has a private orthodontic practice in Portage, Michigan.



Dr. Carano has a private orthodontic practice in Taranto, Italy.

Q: Why is the vertical slot important?

Bowman: The addition of a simple v-slot opens an entire new realm of treatment options and auxiliaries. First of all, the elimination of ball hooks on the brackets significantly reduces the potential tissue impingement, reduces trapped food and plaque, while making arch wire tie-in easier. Besides, a simple T-pin can be added and subtracted anywhere along your appliance when elastics are needed (**Fig. 2**). This virtually eliminates the need for Kobayashi ties or soldered hooks. In addition, a variety of other v-slot auxiliaries are already available including rotating springs, uprighting springs, and power arms for retraction.

Carano: One of the simplest uses of the v-slot is for teeth that are blocked-out or ectopically erupted. In these instances it

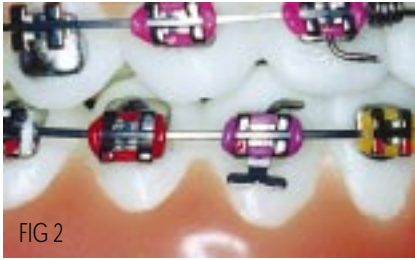


FIG 2

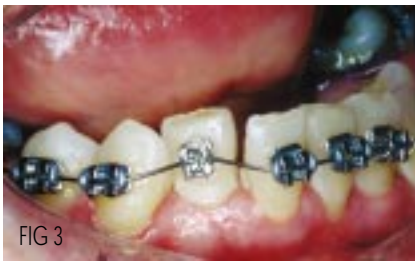

FIG 3

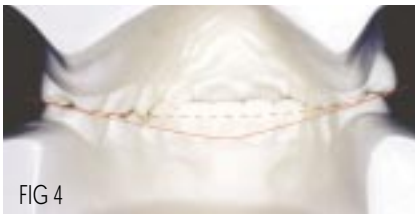

FIG 4

Dotted line = ideal Curve of Wilson
Solid line = excessive buccolingual tipping

is nearly impossible to tie an arch wire into the brackets during early alignment, however, a steel ligature or elastic thread can be placed through the vertical slot to “sling-tie” out and around the arch wire (Fig. 3).

Q: How does the Butterfly System address the most common problems described by the American Board of Orthodontics?

Bowman: Progressive posterior torque was designed into the Butterfly prescription to address improper buccolingual inclination of posterior teeth, the most prevalent error found by the ABO. These errors would seem to be common considering the extreme amount of mandibular posterior lingual crown torque “designed-into” many straightwire prescriptions, in part, to obtain so-called “cortical anchorage”. Compounding this dilemma is the increasingly common use of expansion treatment (often using overexpanded arch blanks) with a prescription that gen-

erally features a limited amount of maxillary posterior lingual crown torque.

Carano: Increased maxillary posterior torque was added to the Butterfly prescription to reduce buccally-tipped molars while reduced mandibular posterior torque is intended to diminish the typical “rolling-in” or linguoversion of mandibular molars that are often seen with straightwire treatments. The combined effect is an improvement in the final buccolingual occlusion by flattening the Curve of Wilson, minimizing posterior overjet, and reducing the prominence of palatal cusps (Fig. 4).

Bowman: If additional posterior torque is to be added or subtracted during treatment, then Beta-Ti wires with 3rd order progressive torque appears to be the most effective and comfortable method compared to using stainless steel wires. By selecting an arch form that demonstrates a more anatomically correct shape (e.g., Natural Arch III) intercuspid widths are maintained and, with appropriate arch coordination, the arch form will approach the original dimensions of the patient’s dental arches (for better posttreatment stability and natural esthetics).

Q: Why are there two options for mandibular anterior torque included in the prescription?

Carano: Some undesired tendencies often occur during straightwire treatment. These include: a tendency for maxillary and mandibular anteriors to be tipped labially (increasing instability, lip protrusion, and taxing anchorage), clockwise rotation of the mandibular plane (increasing Class II relationships and decreasing stability), and extrusion of maxillary incisors (increasing gingival display). Preventative lingual crown torque of -5° in the mandibular anteriors of the Butterfly System is intended to resist the inherent tipping of incisors during leveling. Brackets with an optional -10° of torque are also available and are recommended for use in Class II cases to reduce the labial tipping from Class II elastics or fixed functional appliances like Jasper Jumpers or Herbst.

In 1996, the American Board of Orthodontics reported on the common mistakes found in case reports failing Phase III examination. As some type of pre-adjusted appliance was often used, some shortcomings of existing straightwire concepts may warrant improvements.

Bowman: Reports from Creekmore, Alexander, Gianelly, and Al Qabandi have described the limitations of controlling the labial proclination of incisors during leveling, even with rectangular wires, especially when using Class II elastics. Consequently, lingual crown torque, built into the prescription for lower anterior brackets, has been recommended. Clinicians may wish to keep about 20% of their inventory as -10° mandibular anterior brackets and the remainder as the standard -5° . These two torque options reduce the amount of wire-bending required to compensate for labially-tipped incisors. If less torque is desired, simply use smaller dimension rectangular wires to express less torque.

Q: What about angulation in the mandibular anteriors?

Bowman: The ABO was specifically concerned about errors in anterior root angulation. Progressive mandibular mesial crown tip in the anterior brackets was designed to reduce those errors and improve stability of finished cases by “tent-posting” the incisors. This will reduce the distal crown tip of lower incisors and undesirable convergence of the roots.

Carano: The combination of preventative anterior torque and angulation seem to be important factors to enhance not only esthetics of the finished

smile and profile but also the stability of the final result.

Q: Was the ABO also concerned about errors in marginal ridge match for finished cases?

Bowman: Yes, third in prevalence of problems noted by the ABO were marginal ridge discrepancies with 55% of the errors found between the maxillary and mandibular 1st and 2nd molars and 33% found between the 2nd premolars and 1st molars. This dilemma arises due to differences in heights of the mesial and distal marginal ridges of primarily the maxillary 1st molar. Standard molar bands are frequently positioned too gingivally in the distal aspect, thereby tipping the molar buccal tube distally. The result is prominence of the distobuccal cusps of the first molar, marginal ridge discrepancies, and occlusal interferences.

Carano: The Butterfly System helps to address these concerns in a number of ways. First, we have added -6° of tip to the pre-welded attachment on the first molar band to help compensate for the noted difference in the mesial and distal marginal ridge height of the first molar. This addition compensates for the band positioning errors noted by the ABO.

Q: What type of molar tube is suggested for the Butterfly System?

Bowman: Although bonding brackets on molars has become more prevalent, the versatility of a triple buccal tube on a maxillary first molar band has numerous advantages. The convertibility of the main buccal tube permits easier application of larger arch wires to both 1st and 2nd molars while the auxiliary tube facilitates the simple application of secondary sectional or continuous arch wires. Finally, the headgear tube is useful for the addition of cervical headgear, fixed functionals (e.g., Jasper, Gentle, or Ribbon Jumpers), Korn lip bumpers, or other auxiliaries.

Q: What other features of the Butterfly System assist in marginal ridge adaptation?

Carano: Offset bonding bases on pre-

molar brackets feature larger bonding surfaces to increase bond strength and also make bond positioning easier to visualize. The offset also permits the bracket to be placed more gingivally to improve marginal ridge match.

Bowman: Mesial crown tip of 3° has been designed into the 2nd premolar bracket prescription for non-extraction cases to reduce marginal ridge discrepancies between the 2nd premolar and 1st molar. For added versatility, these brackets can be reversed to the contralateral side in extraction treatments to improve root paralleling between the 2nd premolar and canine during space closure. (Fig. 5).

Q: What solutions are offered for the overjet problems described by the ABO?

Carano: Both anterior and posterior overjet problems can be improved by appropriate buccolingual torque and the selection of more anatomical arch forms. The adjustment in progressive torque in the Butterfly System (reduced values in the mandibular posteriors and increased in the maxillary) helps to reduce flared maxillary molars and rolled-in mandibular posteriors.

Bowman: The management of arch form suffers from the contemporary use of significantly overexpanded arch blanks. When these broad arch forms are combined with the increasingly popular expansive treatment therapies, the result may include: a flared dentition, a discrepancy in overjet both anteriorly and posteriorly, and distal tip to incisor crowns. The effect is the “orthodontic look” described by Bill Proffit (Fig. 6). It is important to select an arch form that, whenever possible, is similar to the patient’s pretreatment shape while also attempting to maintain the pretreatment intercanine widths to improve stability. Coordination of the arch forms throughout treatment should be accomplished with these principles in mind. The goal is to produce a stable, yet “natural appearance.” My signature should not appear on my orthodontic artwork, or in other words, the patient should not look like they had orthodontic care: overly-expanded smiles with

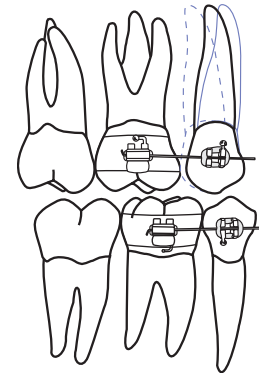
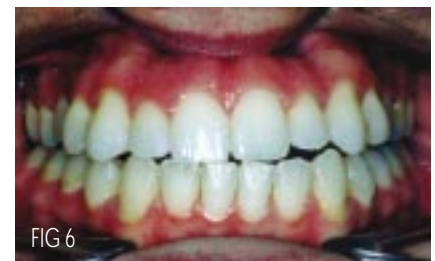

FIG 5
Solid line = extraction (-3° angulation)
Dotted line = non-extraction ($+3^\circ$ angulation)

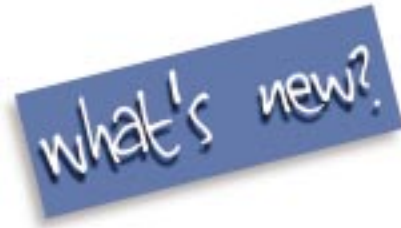

flared incisors or overly-upright and retracted incisors.

Q: In summary, what considerations went into developing a new bracket system?

Bowman: Esthetics, comfort, and versatility are all aspects that come to mind. The Butterfly Bracket System is an esthetic, miniature twin bracket that features the added advantages and versatility of a vertical slot. However, the bracket is lower in profile and features radiused corners on the tie-wings to increase patient comfort. Additionally, the generous tie-wing undercuts make ligation easy, allowing for colorful ligatures during treatment. The Butterfly System is based on modifications in the pre-adjusted concept that were made in response to documented case completion problems as described by the ABO.

Carano: Dr. Bowman and I look forward to collaborating on not only the Butterfly System, but also many other aspects of orthodontic care in an effort to make small but continual improvements in clinical practice. To paraphrase George Eliott, “What is life for if not to make life easier for our patients and ourselves?”



Stealth

The Stealth lingual bracket system addresses the key issues that clinicians have been asking for. A patented "choke" design provides positive seating for full wire control. A smaller, smoother footprint gives greater patient comfort with increased interbracket distance. A vertical slot offers the option for complete system mechanics.



IC Tip

Orthodontic refrigerant spray makes memory type arch wires more pliable. Fast, single step procedure uses a small tube with a ball of cotton at the end to collect the spray as it leaves the can. The end of the cotton then freezes and is pressed against the wire to soften it.



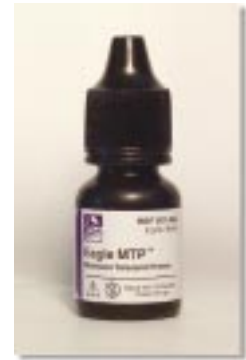The Butterfly System

Developed by Dr. Bowman and Dr. Carano, the Butterfly System uses low profile, vertical slot brackets to achieve superior results.



Virage

The clear choice in ceramics, Virage brackets feature beautifully clear aesthetics with enhanced sliding performance. The palladium gold alloy slot insert is 100% nickel free. A mechanical lock base with dove-tail grooves increases mechanical retention.



Eagle MTP

A moisture tolerant primer that bonds ideally to moist tooth surfaces. Eagle MTP is used during bonding after the etchant is removed with water spray.



Mini Master Series LP (low profile vertical slot)

Offering the perfect balance between comfort and precision, "LP" Brackets feature Diagonal Torque and Diagonal Angulation coupled with smooth, rounded tie wings that are remarkably easy to ligate.